

Detection of breast microcalcifications with super-resolution ultrasound imaging: A clinical study

Lianjie Huang^a, Yassin Labyed^a, Kenneth Hanson^a,
Daniel Sandoval^b, Jennifer Pohl^b, and Michael Williamson^b

^aLos Alamos National Laboratory, MS D452, Los Alamos, NM 87545

^bDepartment of Radiology, University of New Mexico, Albuquerque, NM 87131

ABSTRACT

Imaging breast microcalcifications is crucial for early detection and diagnosis of breast cancer. It is challenging for ultrasound to image breast microcalcifications. Synthetic-aperture ultrasound imaging has the potential to significantly improve ultrasound imaging. Our custom-built, real-time synthetic-aperture ultrasound system makes it possible for clinical studies of super-resolution ultrasound imaging. We recently developed a super-resolution ultrasound imaging method based on the phase-coherent multiple-signal-classification (PC-MUSIC). The method accounts for the phase response of transducer elements to improve image resolution. In this paper, we investigate the clinical feasibility of our super-resolution ultrasound imaging method for detecting breast microcalcifications. We use our synthetic-aperture ultrasound system to acquire breast ultrasound data for 40 patients whose mammograms show the presence of breast microcalcifications. We apply our super-resolution ultrasound imaging method to the patient data, and produce clear images of breast calcifications. Synthetic-aperture ultrasound with our super-resolution PC-MUSIC imaging algorithm provides a new imaging modality for detection of breast microcalcifications.

Keywords: Breast microcalcification, multiple-signal-classification, phase-coherent, super-resolution, synthetic-aperture ultrasound, ultrasound imaging.

1. INTRODUCTION

Breast imaging is to detect microcalcifications and characterize breast masses. It is crucial to be able to detect breast microcalcifications for early cancer detection and diagnosis because breast microcalcifications are the first sign of numerous cases of breast cancer. Ultrasound imaging could be an attractive alternative tool for detecting breast microcalcifications. However, it is difficult for breast ultrasound to detect microcalcifications because they are often invisible within the noisy echo texture.¹⁻⁴ Some alternate techniques have been developed to improve ultrasound imaging,^{2,5-7} such as vibro-acoustography and photoacoustic imaging.

Synthetic-aperture ultrasound has great potential to significantly improve medical ultrasound imaging.⁸⁻²² Synthetic-aperture ultrasound with high-resolution imaging algorithms is a promising imaging modality for detecting breast microcalcifications.^{19,21-30} Particularly, we have recently developed a suite of super-resolution ultrasound imaging methods for detection of breast microcalcifications.²⁷⁻³² Our new methods are based on time-reversal imaging with multiple signal classification (TR-MUSIC)³³ and the phase-coherent MUSIC (PC-MUSIC) imaging.³⁴

We have used our custom built, real-time synthetic-aperture ultrasound system (InnerVision DAS009) to acquire breast ultrasound data for patients whose mammograms show the presence of breast calcifications.²² This new synthetic-aperture ultrasound system is capable of acquiring synthetic-aperture ultrasound data and forming ultrasound images in real time. Our imaging results of phantom studies showed that the new synthetic-aperture ultrasound system can produce images of small targets with higher resolution and less image artifacts than conventional ultrasound systems such as Acuson Sequoia 512 and Siemens S2000.²¹

The PC-MUSIC ultrasound imaging with compensation for the phase response of transducer elements is the most robust method among the super-resolution ultrasound imaging methods we recently developed.³¹ Our PC-MUSIC imaging of a tissue-mimicking phantom containing tiny glass spheres shows that its image resolution is comparable to X-ray mammography. In this paper, we study the *in vivo* imaging capability of our PC-MUSIC imaging method for detecting

Send correspondence to Lianjie Huang: ljh@lanl.gov



Figure 1: Our custom built, real-time synthetic-aperture ultrasound system (InnerVision DAS009) with a Prosonic HL5-10/40EPN transducer. The machine has a maximum frame rate of 25 Hz, and is capable of acquiring synthetic-aperture ultrasound data and forming ultrasound images in real time.

breast microcalcifications. We recruit patients whose mammograms show the presence of breast microcalcifications. We then use our synthetic-aperture ultrasound machine to scan the regions with microcalcifications, obtain synthetic-aperture ultrasound images, and acquire ultrasound data for super-resolution imaging. We conduct PC-MUSIC imaging with the response of transducer elements, and compare the imaging results with synthetic-aperture ultrasound images. Our clinical study demonstrates that super-resolution ultrasound PC-MUSIC imaging can produce clear images of breast microcalcifications, and could provide a novel and safe imaging modality for detection of breast microcalcifications in clinic.

2. PC-MUSIC IMAGING METHOD ACCOUNTING FOR THE TRANSDUCER PHASE RESPONSE

In a synthetic-aperture ultrasound system, each transducer element is fired sequentially and all transducer elements record ultrasound backscattered/reflection signals simultaneously, yielding the inter-element response matrix K . In our recently developed modified PC-MUSIC imaging method that accounts for the phase response of transducer elements, the pseudo-spectrum P is given by³¹

$$P(\mathbf{r}) = \frac{1}{1 - \sum_{\omega} A(\mathbf{r}, \omega)}, \quad (1)$$

where \mathbf{r} is the spatial imaging point, ω is the angular frequency, and the term A is given by

$$A(\mathbf{r}, \omega) = e^{-i\phi(\omega)} \frac{G^H(\mathbf{r}, \omega) U_{sig}(\omega) V_{sig}^H(\omega) G^*(\mathbf{r}, \omega)}{\|G(\mathbf{r}, \omega)\|^2}, \quad (2)$$

where $\phi(\omega)$ is the phase response of transducer elements, G is Green's function, superscript H is the Hermitian, or the conjugate transpose, superscript $*$ is the complex conjugate, U and V are the unitary matrices from the singular value decomposition of the inter-element response matrix K .

We apply our PC-MUSIC imaging method to patient data to study the clinical feasibility for detecting breast microcalcifications.

3. PHANTOM IMAGING

Our custom-built, real-time synthetic-aperture ultrasound system (InnerVision DAS009) is an investigational device (Fig. 1). A Prosonic HL5-10/40EPN transducer with 128 elements is used to acquire synthetic-aperture ultrasound data. The center


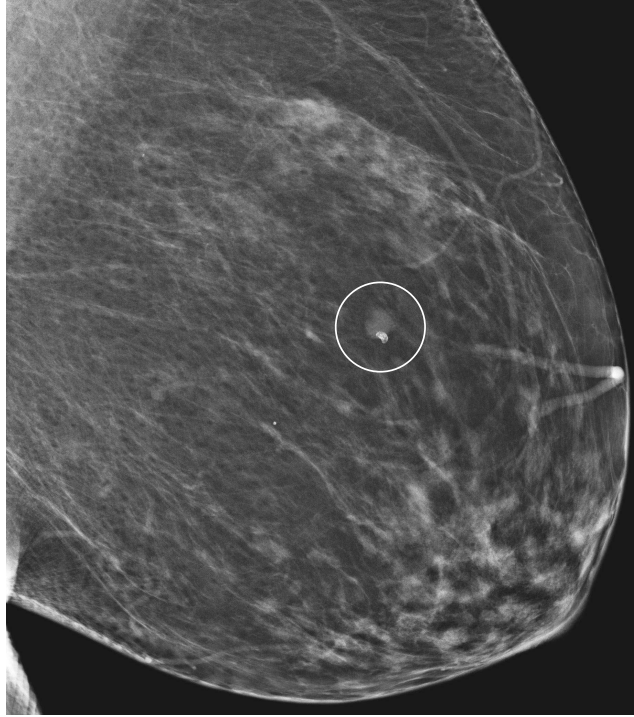


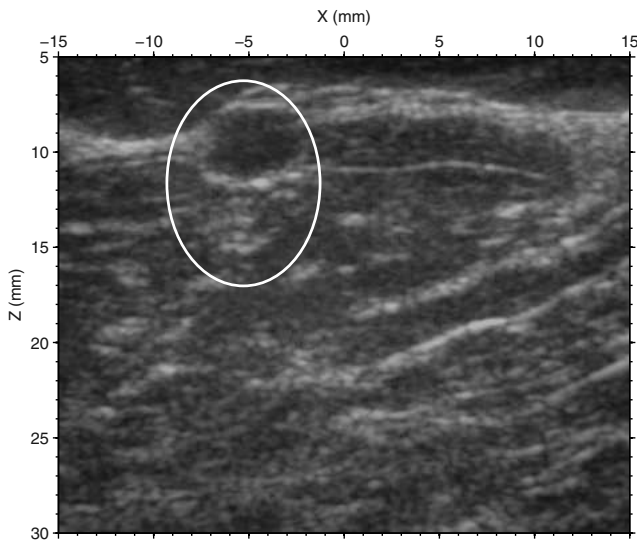
Figure 2: Images of a tissue-mimicking phantom containing a homogeneous background and numerous glass spheres with an average diameter of $250\ \mu\text{m}$. The images are obtained using (a) mammography, (b) synthetic-aperture imaging, (c) our modified PC-MUSIC with compensation for the phase response of the transducer elements. The image in (c) is comparable to that in (a).

frequency of the transducer array is approximately $7.5\ \text{MHz}$ and the 6-dB fractional bandwidth of approximately 65%. The possible selections of the frame rate for our synthetic-aperture ultrasound system are 5, 10, 15, 25 Hz. The high frame rate of this system makes it possible to use synthetic-aperture ultrasound to obtain synthetic-aperture ultrasound images and acquire ultrasound data in real time. This investigational ultrasound system provides radio-frequency (RF) data for additional imaging.

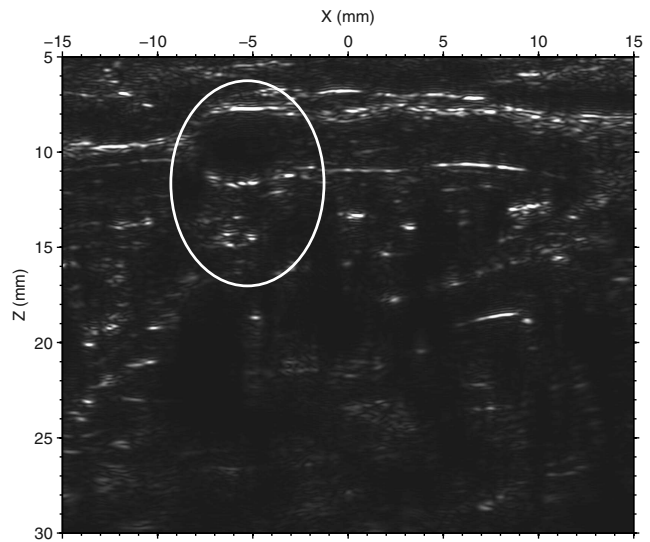
We demonstrate the improved imaging capability of our PC-MUSIC imaging method with phantom data acquired using our synthetic-aperture ultrasound system. The tissue-mimicking phantom contains numerous tiny glass spheres along a plane within a homogeneous background medium. The diameters of the tiny glass spheres are approximately $250\ \mu\text{m}$. We scan the phantom using our synthetic-aperture ultrasound system, acquire ultrasound data, and conduct PC-MUSIC imaging with the data. Figure 2 shows images obtained with different imaging modalities. Panel (a) of Fig. 2 is an X-ray mammography image of the phantom with the inverted grayscale for better comparison with ultrasound images. The synthetic-aperture ultrasound image in Fig. 2(b) has a lower resolution compared to the X-ray mammography image



(a) Mammogram



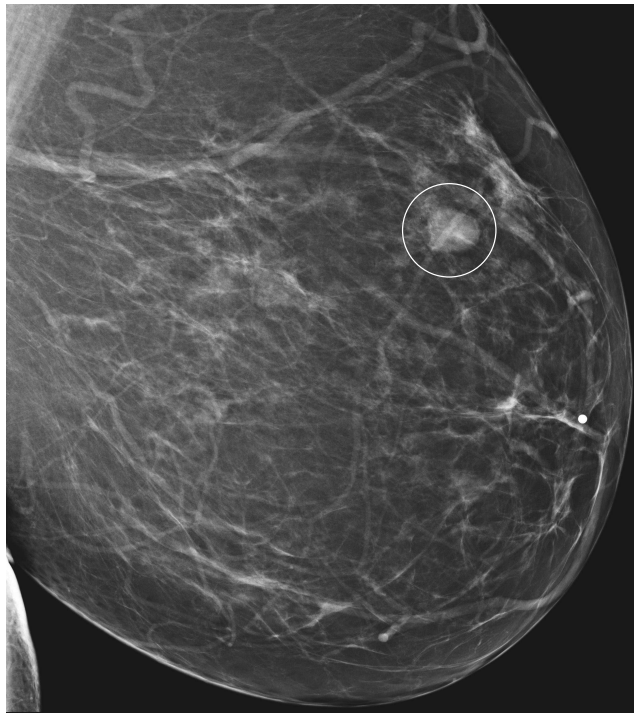(b) Synthetic-aperture ultrasound image



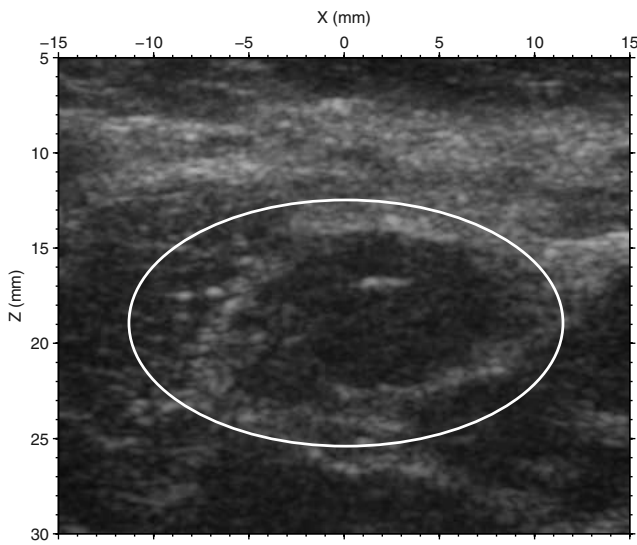
(c) Super-resolution PC-MUSIC image

Figure 3: Images of a patient breast obtained with (a) mammography, (b) synthetic-aperture ultrasound, and (c) our PC-MUSIC imaging method. Calcifications around a 5-mm cyst in a patient's left breast shown within the circled region on the mammogram in (a) are clearly imaged using our PC-MUSIC imaging method as shown in (c), but they are almost invisible in the synthetic-aperture ultrasound image in (b), as shown in the elliptical regions in (b) and (c).

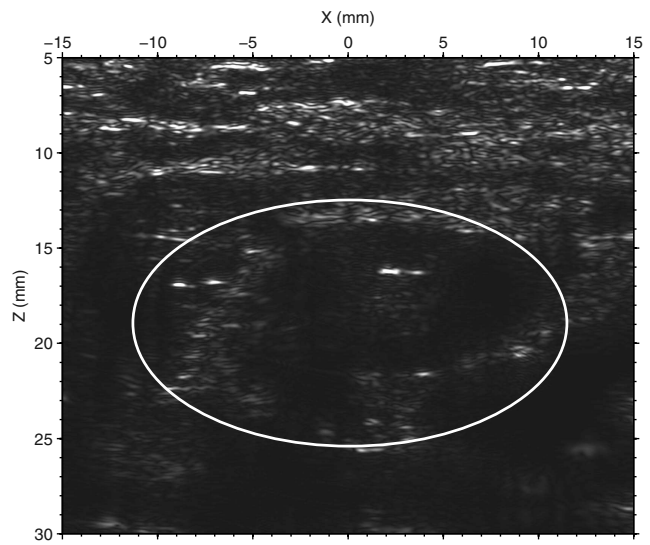
in Fig. 2(a). In the synthetic-aperture ultrasound image, the glass spheres appear larger than their actual sizes, and some closely-separated spheres appear as one. Although the glass spheres are the only inhomogeneities in the phantom, the synthetic-aperture ultrasound image still contains speckle noise, which is possibly caused by multiple scattering among the glass spheres. Our PC-MUSIC imaging as shown in Fig. 2(c) significantly reduces the image speckle, and produces clear



(a) Mammogram

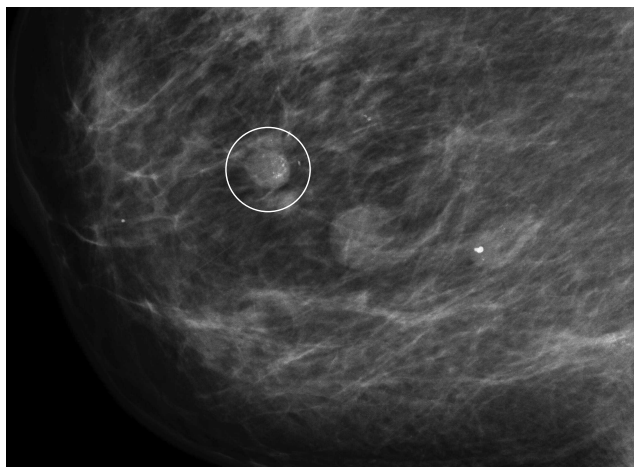


(b) Synthetic-aperture ultrasound image

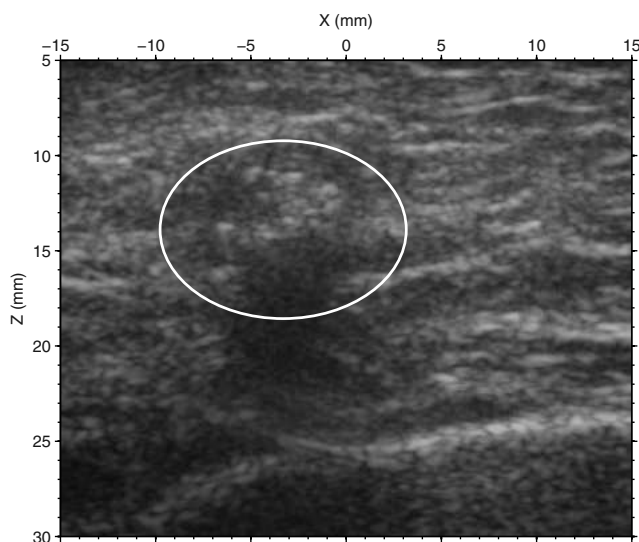


(c) Super-resolution PC-MUSIC image

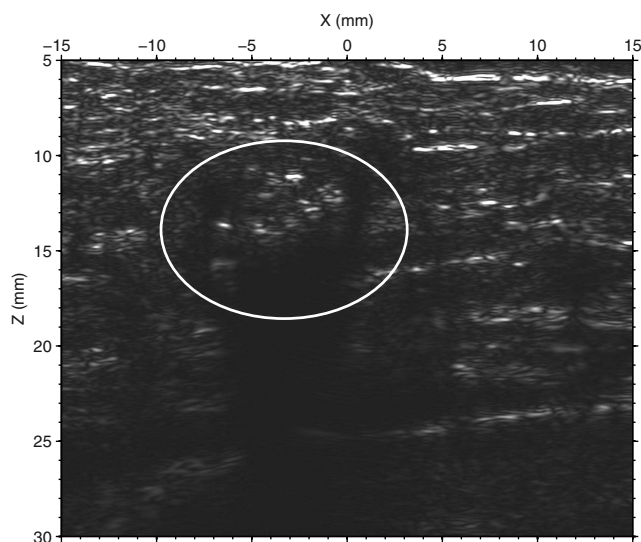
Figure 4: Images of a patient breast obtained with (a) mammography, (b) synthetic-aperture ultrasound, and (c) our PC-MUSIC imaging method. The mammogram of a patient's left breast in (a) indicates that the patient has a 10-mm breast mass with calcifications inside and outside the mass, as shown in the circled region. Our PC-MUSIC imaging produces much more clear images of calcifications inside and outside the breast mass than synthetic-aperture ultrasound does, as shown within the elliptical regions in (b) and (c).



(a) Mammogram



(b) Synthetic-aperture ultrasound image



(c) Super-resolution PC-MUSIC image

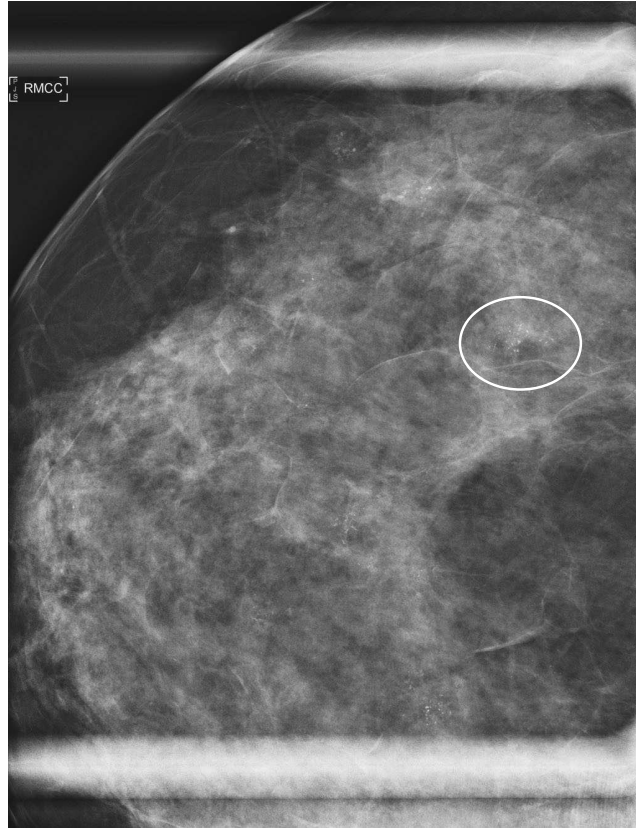Figure 5: Images of a patient breast obtained with (a) mammography, (b) synthetic-aperture ultrasound, and (c) our PC-MUSIC imaging method. The circled region on the mammogram of a patient's right breast shows an 8-mm mass with microcalcifications. These microcalcifications are much more clearly imaged using our PC-MUSIC method than using synthetic-aperture ultrasound, as shown within the elliptical regions in (b) and (c).

images of all tiny glass spheres. The spatial image resolution of the PC-MUSIC image in Fig. 2(c) is much higher than that of the synthetic-aperture image in Fig. 2(b), and is comparable to that of the X-ray mammography in Fig. 2(a).

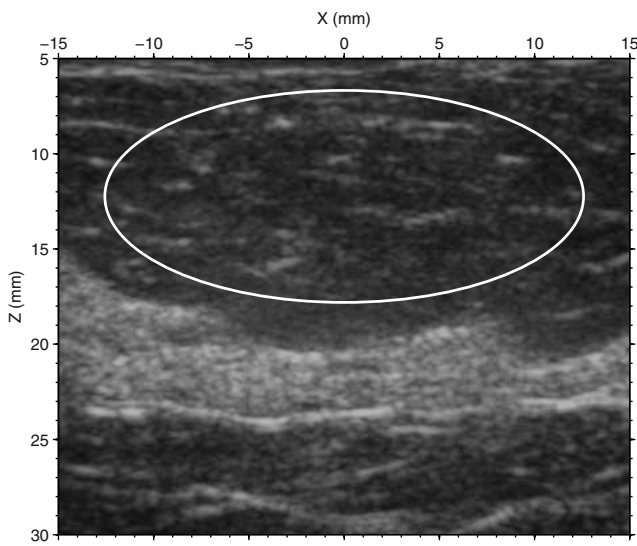
4. PATIENT RECRUITMENT AND PATIENT DATA ACQUISITION

We recruit patients under a clinical protocol approved by the Institutional Review Board (IRB) of the University of New Mexico School of Medicine. Approximately 8,000 patients per year receive screening mammography at the University of New Mexico Hospital, and an additional of approximately 2,000 patients have diagnostic mammograms. About 800 of these patients have some abnormalities on their mammograms. Further evaluation with additional imaging is required for these patients, including mammography and often ultrasound. 200–300 patients of these 800 patients with an abnormality have breast microcalcifications that need to be characterized.

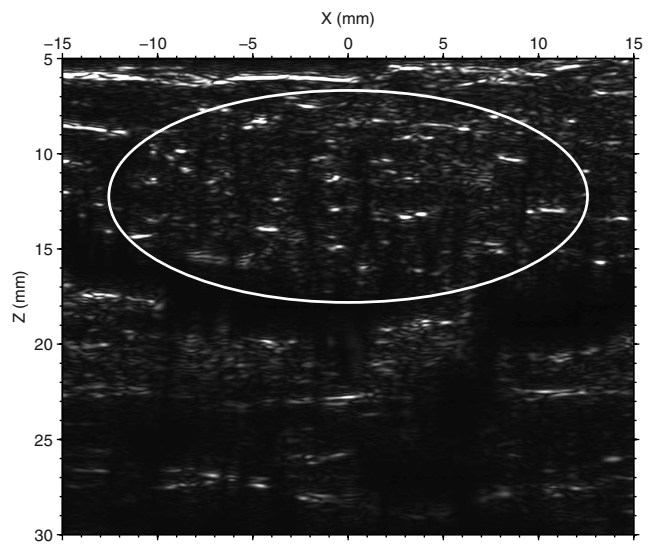
If microcalcifications are detected on screening mammograms, magnification mammography and breast ultrasound are



(a) Mammogram



(b) Synthetic-aperture ultrasound image



(c) Super-resolution PC-MUSIC image

Figure 6: Images of a patient breast obtained with (a) mammography, (b) synthetic-aperture ultrasound, and (c) our PC-MUSIC imaging method. The mammogram of a patient's right breast in (a) shows that there are numerous distributed clusters of breast microcalcifications in the breast. Our PC-MUSIC image of the breast calcifications corresponding to the elliptical area in (a) has a much higher image resolution than that of synthetic-aperture ultrasound, as shown within the elliptical regions in (b) and (c).

performed in an effort to characterize the calcifications as likely malignant or likely benign. The purpose of imaging using the conventional ultrasound is mainly for detecting any masses that may be associated with the calcifications.

We identify patients who have had microcalcifications identified on their screening mammograms and are undergoing routine magnification ultrasound exam. The mammographer, who identifies a patient in need of follow-up imaging, notifies the study coordinator that this patient may be eligible for the study. When the patient is contacted to schedule the clinical imaging, the study coordinator asks the patient whether she would be interested in the possibility of participating in scanning with the synthetic-aperture ultrasound system (Fig. 1) provided by Los Alamos National Laboratory (LANL). The coordinator reads a recruitment script to potential participants, answers questions, and arranges to have consent administered when the potential participants arrive for their scheduled clinical imaging.

Consent administration occurs in a private area at the time of the potential participants' clinical follow-up imaging appointment. The study coordinator provides interested patients with a consent form. The consent form is reviewed with the patient and the patient is given an opportunity to ask questions. To ensure understanding, the study coordinator asks the patient to explain the study in their own words. The study coordinator emphasizes to the patient that their decision to participate will not affect their right to medical care. Synthetic-aperture ultrasound imaging is purely for research purpose, and is not used for diagnostic purpose or patient care. Scan with LANL's synthetic-aperture ultrasound system takes place after completion of the consent process.

5. *IN VIVO* PATIENT IMAGING

We conduct PC-MUSIC imaging with breast ultrasound data acquired using LANL's synthetic-aperture ultrasound system, and compared the results with synthetic-aperture ultrasound images. We present the results for four patients with breast calcifications in their breasts. The first patient has a small cyst in her left breast with calcifications around the cyst. The second patient's left breast has a 10-mm breast mass with calcifications inside and outside the mass. The third patient has an 8-mm mass with microcalcifications inside the mass in her right breast. The last patient's right breast contains distributed clusters of calcifications in her right breast. All these four patients underwent biopsy.

It is challenging to use one-dimensional ultrasound array to image the correct regions within three-dimensional breasts even though patients' mammograms shows calcifications. The reason is that the images of microcalcifications shown on mammograms are their projection images, and it is difficult for radiologists to know the exact regions containing breast microcalcifications. Therefore, ultrasound images for a number of patients recruited do not contain microcalcifications. For imaging the first three patients presented in this paper, we use images of the breast cyst and masses as a reference to confirm the locations of breast calcifications.

The screening mammogram of a 70-year-old patient shows a small cyst in her left breast, as indicated within the circled region of Fig.3(a). The size of the small mass is approximately 5 mm with calcifications around the cyst. These calcifications are poorly imaged using the synthetic-aperture ultrasound, see displayed in the elliptical region in Figure 3(b). By contrast, our PC-MUSIC imaging as shown in Figure 3(c) clearly detects these calcifications (see the elliptical region).

The mammogram of the second patient shows that she has a 10-mm mass in her left breast with calcifications inside and outside the mass, as shown in the circled region in Fig. 4(a). She is 44 years old. Our PC-MUSIC imaging produces much more clear images of these calcifications than synthetic-aperture ultrasound does, as shown within the elliptical regions in Figs. 4(b) and (c).

As shown in the circled region of the mammogram in Figure 5(a) of the third patient, she has an 8-mm mass in her right breast. The breast mass of this 60-year-old woman also contains numerous microcalcifications. These microcalcifications are much more clearly imaged using our PC-MUSIC method than using synthetic-aperture ultrasound, as shown within the elliptical regions in Figs. 5(b) and (c).

The mammogram of the right breast of the fourth patient shows distributed clusters of microcalcifications, as displayed within the elliptical area in Fig. 6(a) and many other regions throughout the breast. We use LANL's synthetic-aperture ultrasound system to scan the region corresponding to the elliptical area in Fig. 6(a), and obtain the synthetic-aperture ultrasound image in Fig. 6(b). Our PC-MUSIC imaging result displayed in Fig. 6(c) gives much better images of the breast microcalcifications than the synthetic-aperture ultrasound imaging in the elliptical area in Fig. 6(b).

6. CONCLUSIONS

We have investigated the clinical feasibility of our super-resolution phase-coherent multiple-signal-classification (PC-MUSIC) imaging method for detection of breast microcalcifications. Our PC-MUSIC imaging method accounts for the phase response of transducer elements. We have applied the method to *in vivo* patient data acquired using our custom-built, real-time synthetic-aperture ultrasound system. We use the images of breast masses or cysts as a reference to confirm locations of imaged breast calcifications. Our PC-MUSIC imaging produces images of breast microcalcifications with a much higher resolution than those obtained using synthetic-aperture ultrasound. Our initial clinical study demonstrates that synthetic-aperture ultrasound with our super-resolution PC-MUSIC imaging algorithm is a promising imaging modality for detection of breast microcalcifications.

7. ACKNOWLEDGMENTS

This work was supported by the Breast Cancer Research Program of U.S. DOD Congressionally Directed Medical Research Programs. We thank Christine Wipf of the University of New Mexico for her help in recruiting and scanning patients.

REFERENCES

- [1] Anderson, M. E., Soo, M. S., Bentley, R. C., and Trahey, G. E., "The detection of breast microcalcifications with medical ultrasound," *JASA* **101**, 29–39 (1997).
- [2] Anderson, M. E., Soo, M. S. C., and Trahey, G. E., "Microcalcifications as elastic scatterers under ultrasound," *IEEE Trans. Ultrason. Ferroelectr. Freq. Control* **45**, 925–934 (1998).
- [3] Alizad, A., Fatemi, M., Wold, L. E., and Greenleaf, J. F., "Performance of vibro-acoustography in detecting microcalcifications in excised human breast tissue: A study of 74 tissue samples," *IEEE Trans. Med. Imaging* **23**, 307–312 (2004).
- [4] Nagashima, T., Hashimoto, H., Oshida, K., Nakano, S., Tanabe, N., Nikaido, T., Koda, K., and Miyazaki, M., "Ultrasound demonstration of mammographically detected microcalcifications in patients with ductal carcinoma in situ of the breast," *Breast Cancer* **12**, 216–220 (2005).
- [5] Yang, W. T., Suen, M., Ahuja, A., and Metreweli, C., "In vivo demonstration of microcalcification in breast cancer using high resolution ultrasound," *The British Journal of Radiology* **70**, 685–690 (1997).
- [6] Alizad, A., Whaley, D. H., Greenleaf, J. F., and Fatemi, M., "Critical issues in breast imaging by vibro-acoustography," *Ultrasonics* **44**, e217–e220 (2006).
- [7] Kang, J., Kim, E.-K., Kwak, J. Y., Yoo, Y., Song, T.-K., and Chang, J. H., "Optimal laser wavelength for photoacoustic imaging of breast microcalcifications," *Applied Physics Letters* **99**, 153702 (2011).
- [8] O'Donnell, M. and Thomas, L. J., "Efficient synthetic aperture imaging from a circular aperture with possible application to catheter-based imaging," *IEEE Transactions on Ultrasonics, Ferroelectrics, and Frequency Control* **39**, 366–380 (1992).
- [9] Lockwood, G., Talman, J., and Brunke, S., "Real-time 3-d ultrasound imaging using sparse synthetic aperture beam-forming," *IEEE Trans. Ultrason. Ferroelectr. Freq. Control* **45**, 980–988 (1998).
- [10] Nikolov, S., Gammelmark, K., and Jensen, J., "Recursive ultrasound imaging," *Proceedings of the IEEE Ultrasonic Symposium* **2**, 1621–1625 (1999).
- [11] Nikolov, S. I., *Synthetic aperture tissue and flow ultrasound imaging*, PhD thesis, PhD Thesis, Technical University of Denmark (2001).
- [12] Jensen, J., Holm, O., Jensen, L., Bendsen, H., Nikolov, S., Tomov, B., Munk, P., Hansen, M., Salomonsen, K., Hansen, J., Gormsen, K., Pedersen, H., and Gammelmark, K., "Ultrasound research scanner for real-time synthetic aperture data acquisition," *IEEE Trans. Ultrason. Ferroelectr. Freq. Control* **52**, 881–891 (2005).
- [13] Jensen, J., Nikolov, S., Gammelmark, K., and Pedersen, M., "Synthetic aperture ultrasound imaging," *Ultrasonics* **44**, e5–e15 (2006).
- [14] Daher, N. and Yen, J., "2-d array for 3-d ultrasound imaging using synthetic aperture techniques," *IEEE Trans. Ultrason. Ferroelectr. Freq. Control* **53**, 912–924 (2006).
- [15] Simonetti, F., "Multiple scattering: The key to unravel the subwavelength world from the far-field pattern of a scattered wave," *Physical Review E* **73**, 036619–1–13 (2006).

- [16] Simonetti, F., Huang, L., Duric, N., and Rama, O., "Imaging beyond the born approximation: An experimental investigation with an ultrasonic ring array," *Physical Review E* **76**, 036601–1–10 (2007).
- [17] Simonetti, F. and Huang, L., "From beamforming to diffraction tomography," *Journal of Applied Physics* **103**, 103110–1–7 (2008).
- [18] Andresen, H., Nikolov, S., Pedersen, M., Buckton, D., and Jensen, J., "Three-dimensional synthetic aperture focusing using a rocking convex array transducer," *IEEE Trans. Ultrason. Ferroelectr. Freq. Control* **57**, 1051–1063 (2010).
- [19] Huang, L., Simonetti, F., Huthwaite, P., Rosenberg, R., and Williamson, M., "Detecting breast microcalcifications using super-resolution and wave-equation ultrasound imaging: A numerical phantom study," in [*Ultrasonic Imaging, Tomography, and Therapy*], D'hooge, J. and McAleavey, S. A., eds., *Proc. SPIE* **7629**, 762919–1–10, SPIE (2010).
- [20] Nikolov, S. I., Kortbek, J., and Jensen, J. A., "Practical applications of synthetic aperture imaging," in [*Proceedings – IEEE Ultrasonics Symposium*], 350–358 (2010).
- [21] Huang, L., Labyed, Y., Simonetti, F., Williamson, M., Rosenberg, R., Heintz, P., and Sandoval, D., "High-resolution imaging with a real-time synthetic aperture ultrasound system: A phantom study," in [*Ultrasonic Imaging, Tomography, and Therapy*], D'hooge, J. and Dooley, M. M., eds., *Proc. SPIE* **7968**, 796811–1–10, SPIE (2011).
- [22] Huang, L., Labyed, Y., Lin, Y., Zhang, Z., Pohl, J., Sandoval, D., and Williamson, M., "Detection of breast microcalcifications using synthetic-aperture ultrasound," in [*Ultrasonic Imaging, Tomography, and Therapy*], D'hooge, J. and Dooley, M. M., eds., *Proc. SPIE* **8320**, 83200H–1–8, SPIE (2012).
- [23] Huang, L., Duric, N., and Littrup, P., "Ultrasonic breast imaging using a wave-equation migration method," *Proc. SPIE* **5035**, 432–439 (2003).
- [24] Huang, L., Duric, N., and Littrup, P., "Breast imaging with time-reversed ultrasound," *Proc. SPIE* **6147**, 156–167 (2006).
- [25] Huang, L. and Quan, Y., "Ultrasound pulse-echo imaging using the split-step Fourier propagator," *Proc. SPIE* **6513**, 651305–1–12 (2007).
- [26] Huang, L., Hanson, K. M., Quan, Y., Li, C., and Duric, N., "Globally optimized Fourier finite-difference method for ultrasound breast imaging," *Proc. SPIE* **6920**, 692007–1–11 (2008).
- [27] Labyed, Y. and Huang, L., "Detecting small targets using windowed time-reversal MUSIC imaging: A phantom study," *International Ultrasonics Symposium Proceedings* **10.1109/ULTSYM.2011.0392**, 1579–1582 (2011).
- [28] Labyed, Y. and Huang, L., "Ultrasound imaging of extended targets using a windowed time-reversal MUSIC method," in [*Ultrasonic Imaging, Tomography, and Therapy*], D'hooge, J. and Dooley, M. M., eds., *Proc. SPIE* **8320**, 832019–1–10, SPIE (2012).
- [29] Labyed, Y. and Huang, L., "Ultrasound time-reversal MUSIC imaging with diffraction and attenuation compensation," *IEEE Trans. Ultrason. Ferroelectr. Freq. Control* **59**, 2186–2200 (2012).
- [30] Labyed, Y. and Huang, L., "Ultrasound time-reversal MUSIC imaging of extended targets," *Ultrasound in Med. & Biol.* **38**, 2018–2030 (2012).
- [31] Labyed, Y. and Huang, L., "Super-resolution ultrasound phase-coherent MUSIC imaging with compensation for the phase response of transducer elements," *IEEE Trans. Ultrason. Ferroelectr. Freq. Control* (**Accepted**) (2013).
- [32] Labyed, Y. and Huang, L., "Time-reversal MUSIC ultrasound imaging of small targets with density and compressibility contrasts," *IEEE Trans. Ultrason. Ferroelectr. Freq. Control* (**Under Review**) (2013).
- [33] Devaney, A. J., Marengo, E. A., and Gruber, F. K., "Time-reversal-based imaging and inverse scattering of multiply scattering point targets," *JASA* **118**(5), 3129–3138 (2005).
- [34] Asgedom, E. G., Gelius, L.-J., Austeng, A., Holm, S., and Tygel, M., "Time-reversal multiple signal classification in case of noise: A phase-coherent approach," *JASA* **130**(4), 2024–2034 (2011).